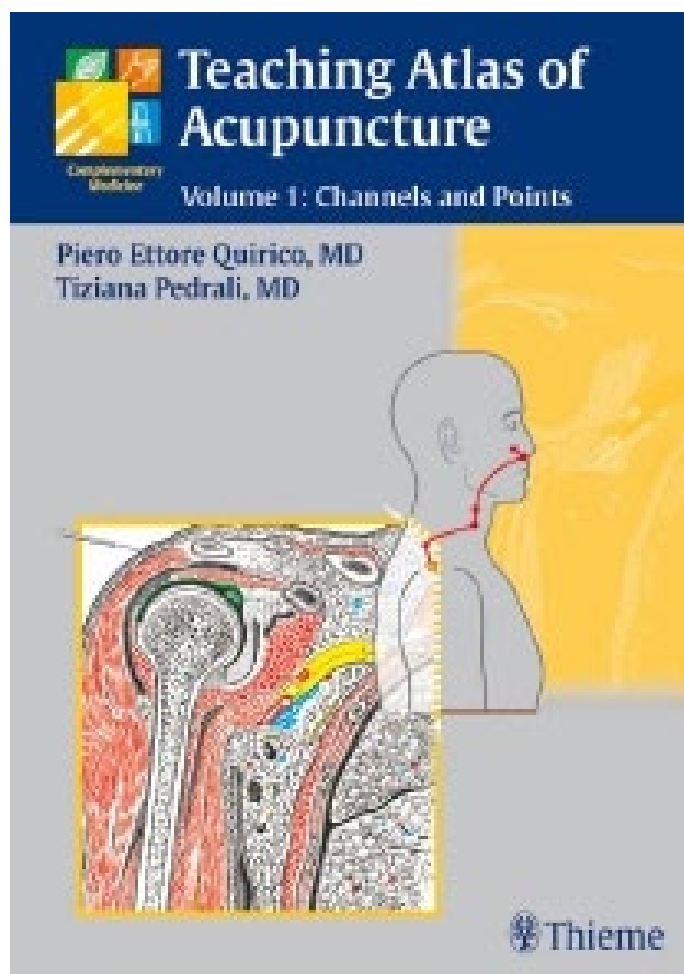




Piero Ettore Quirico

Teaching Atlas of Acupuncture

Volume 1: Channels and Points



zum Bestellen [hier klicken](#)

by naturmed Fachbuchvertrieb

Aidenbachstr. 78, 81379 München

Tel.: + 49 89 7499-156, Fax: + 49 89 7499-157

Email: info@naturmed.de, Web: <http://www.naturmed.de>

Preface

Ten years after the first successful edition of the atlas *Punti e Meridiani di Agopuntura*, we felt the need to modernize and enrich the content of this book, in order to bring it up to date and closer to the requirements of acupuncturists and acupuncture students.

The original plan of a corrected and integrated re-edition of the atlas was, during its long processing time, gradually left behind. We decided to create a new book that would, even if it maintained the iconography of the former edition, in reality be completely updated and revised in its content and in its general layout to produce a much more exhaustive yet concise and easy-to-use reference work. We are very happy to have the opportunity to review this new English edition of our book, and we thank Thieme Publishers for this interesting opportunity.

Over the past 15–20 years, European acupuncture has finally confronted itself with the Chinese discipline and has been obliged to revise and correct a large part of its doctrinal approach, thereby becoming more realistic.

The physiopathology of the internal organs and their syndromic patterns has been accepted by most acupuncture schools. Clinical indications of acupuncture points have been deeply revised, abandoning the strict frameworks of doubtful therapeutic effectiveness.

With this in mind, we have conformed—based on Chinese data—the pathways of the main and secondary channels and the location of some new acupunc-

ture points; artwork, that is, the cartography of the channels and the anatomic tables and sections, has been revised, and we have reviewed some clinical indications for acupuncture points and channels.

The aim of this book is to give acupuncturists and acupuncture students an effective learning and reference tool that can accurately provide the location, method of locating, anatomic relations, and main clinical indications for every acupuncture point.

Therapeutic acupuncture techniques often require a deep insertion of the needle, and the danger of provoking internal injuries is very high; for this reason the acupuncturist must have a strict knowledge of the different anatomic layers and of the cross-sections at the level of the acupuncture points.

Insertion of the needle into the acupuncture point cannot be separated from the achievement of the typical paraesthetic sensation named *de qi*, which confirms that the acupuncture point is being correctly stimulated. The first section of this book contains the *de qi* method for each acupuncture point and the detailed information on location, anatomic coordinates, and clinical indications.

Leaving it up to our readers to judge whether our goals have been reached, we present our new atlas and hope to provide students and qualified acupuncturists with a valuable support in their study and clinical practice of acupuncture.

The Authors

Contents

The Authors	VI	E – <i>Yīn Qiāo Mài</i> Extra Channel	
Foreword to the Italian Edition	VII	<i>Yīn</i> Springing Vessel	152
Preface	IX	F – <i>Yáng Qiāo Mài</i> Extra Channel	
How to use the Atlas	X	<i>Yáng</i> Springing Vessel	154
		G – <i>Yīn Wéi Mài</i> Extra Channel	
		<i>Yīn</i> Linking Vessel	156
		H – <i>Yáng Wéi Mài</i> Extra Channel	
		<i>Yáng</i> Linking Vessel	158
Section 1 General Part	1	Chapter 5 The Extra Points	161
Chapter 1 General Tables	3	A – Head and Neck	162
A – Anterior	4	B – Trunk	163
B – Lateral	5	C – Upper Limb	164
C – Posterior	6	D – Lower Limb	165
Chapter 2 The Unit of Proportional Measurement: The “Cun”	7		
Chapter 3 The 12 Regular Channels		Section 2 Analytical Section	181
<i>Jīng Mài</i>	9	Anatomic–Topographic Study of Meridians and Acupuncture Points	181
A – Hand Great <i>Yīn</i> Lung Channel	10	Chapter 6 Head and Neck	183
B – Hand <i>Yang</i> Brightness Large Intestine Channel	16	A – Anterior Aspect	184
C – Foot <i>Yang</i> Brightness Stomach Channel	24	B – Lateral Aspect	186
D – Foot Greater <i>Yīn</i> Spleen Channel	40	C – Posterior Aspect	190
E – Hand Lesser <i>Yīn</i> Heart Channel	48	D – Superior Aspect and Ocular Region	192
F – Hand Greater <i>Yang</i> Small Intestine Channel	52	E – Sections	194
G – Foot Greater <i>Yang</i> Bladder Channel	60	Chapter 7 Trunk	203
H – Foot Lesser <i>Yīn</i> Kidney Channel	80	A – Anterior Aspect	204
I – Hand Reverting <i>Yīn</i> Pericardium Channel	90	B – Lateral Aspect	207
J – Hand Lesser <i>Yáng</i> Triple Burner Channel	96	C – Posterior Aspect	209
K – Foot Lesser <i>Yáng</i> Gallbladder Channel	104	D – Sections	212
L – Foot Reverting <i>Yīn</i> Liver Channel	118	Chapter 8 Upper Limbs	217
Chapter 4 The Eight Extra Channels	127	A – Anterior Aspect	218
A – <i>Rèn Mài</i> Extra Channel Controlling Vessel	128	B – Lateral Aspect	222
B – <i>Dū Mǎi</i> Extra Channel Governing Vessel	138	C – Posterior Aspect	225
C – <i>Chōng Mài</i> Extra Channel Thoroughfare Vessel	148	D – Medial Aspect	229
D – <i>Dài Mài</i> Extra Channel Girdling Vessel	150	E – Hand: Dorsal Aspect	232
		F – Hand: Palmar Aspect	235
		G – Sections	238

Chapter 9 Lower Limbs	259	Chapter 13 The 15 Collateral Channels	
A – Anterior Aspect	260	Lùo Mài	343
B – Lateral Aspect	264	A – The Lùo Channel of the Large Intestine	344
C – Posterior Aspect	267	B – The Lùo Channel of the Triple Burner	
D – Medial Aspect	271	(<i>Sān Jiāo</i>)	344
E – Foot: Dorsal Aspect	274	C – The Lùo Channel of the Small Intestine	344
F – Foot: Plantar Aspect	277	D – The Lùo Channel of the Lung	346
G – Sections	280	E – The Lùo Channel of the Pericardium	
		(<i>Xīn Bāo</i>)	346
		F – The Lùo Channel of the Heart	346
Section 3 Other Channels		G – The Lùo Channel of the Stomach	348
and Collateral Channels	305	H – The Lùo Channel of the Gallbladder	348
Chapter 10 The Six Great Channels	307	I – The Lùo Channel of the Bladder	348
A – <i>Juè Yīn</i>	308	J – The Lùo Channel of the Spleen	350
B – <i>Shào Yīn</i>	308	K – The Lùo Channel of the Kidney	350
C – <i>Tài Yīn</i>	308	L – The Lùo Channel of the Liver	350
D – <i>Yàng Míng</i>	309	M – The Lùo Channel of <i>Dù Mài</i>	352
E – <i>Shào Yáng</i>	310	N – The Lùo Channel of <i>Rèn Mài</i>	352
F – <i>Tài Yáng</i>	311	O – Great Lùo Channel of the Spleen	354
Chapter 11 The 12 Channel Sinews		Chapter 14 The 12 Cutaneous Channels	
Jīng Jīn	313	Pí Bù	357
A – Large Intestine Channel Sinew	314		
B – Triple Burner Channel Sinew— <i>Sān Jiāo</i>	315	Section 4 Appendix	359
C – Small Intestine Channel Sinew	316	Chapter 15 Auricular Acupuncture	361
D – Lung Channel Sinew	317	A – Anatomy of the Auricle	362
E – Pericardium Channel Sinew— <i>Xīn Bāo</i>	318	B – Auricular Acupuncture Maps	366
F – Heart Channel Sinew	319	C – Main Points of Chinese Auricular	
G – Stomach Channel Sinew	320	Acupuncture: Location and Clinical	
H – Gallbladder Channel Sinew	322	Indications	368
I – Bladder Channel Sinew	324		
J – Spleen Channel Sinew	326	Chapter 16 Reflex Therapies:	
K – Liver Channel Sinew	328	Neurophysiologic Basics	375
L – Kidney Channel Sinew	330	A – Dermatomes, Myotomes,	
		and Sclerotomes	377
Chapter 12 The Six Pairs of Divergent		B – <i>Mù</i> and <i>Shū</i> Points of the Trunk	382
Channels Jīng Bié	333	C – Viscerocutaneous Reflex Dermalgias	384
A – First Confluence—Divergent Channels		D – Scalp Acupuncture	386
of the Bladder and Kidney	334		
B – Second Confluence—Divergent Channels		Bibliography/Further Reading	389
of the Stomach and Spleen	336	Control Points	
C – Third Confluence—Divergent Channels		of Acupuncture Channels	390
of the Gallbladder and Liver	338	Graphic Representation	
D – Fourth Confluence—Divergent Channels		of Acupuncture Points	391
of the Small Intestine and Heart	340	Alphabetical Index	
E – Fifth Confluence—Divergent Channels		of Acupuncture Points	392
of the Large Intestine and Lung	341	General Index	398
F – Sixth Confluence—Divergent Channels			
of the Triple Burner and Pericardium	342		

C Chōng Mài Extra Channel Thoroughfare Vessel

Main Branch

The *chōng mài* extra channel starts in the pelvic region (**A**₁) and runs downward at the level of the perineum. At CV-1 *huì yīn* it splits into two branches (**A** and **B**); the main branch (**A**) emerges from ST-30 *qì chōng* (from where branch **C** emerges) and runs through the abdomen along the kidney channel. It then reaches the chest, where it splits into branches and travels to the subclavicular region. From here it reaches the throat, runs around the lips, and ends level with the eyes.

Collaterals

- B** from CV-1 *huì yīn* it runs internally along the lumbar and dorsal spine.
- C** it starts from ST-30 *qì chōng* and runs along the medial surface of the thigh and lower leg. It passes beyond the posterior aspect of the medial malleolus, sends out branch **D** and ends on the plantar surface of the foot.
- D** it splits from branch **C** in the retromalleolar region and ends at the tip of the first toe, after running along the medial arch of the foot.

Function

Chōng mài is the vessel connecting all the main and secondary channels; for this reason it is also called the “sea of the 12 channels” and the “sea of blood.” Its origin from the kidney and its pathway across the points related to this *zàng* show *chōng mài* influence

on the reproductive function, especially on uterine physiology and on pregnancy. In addition *chōng mài* runs through the abdominal region and therefore also acts on the gastroenteric system, specifically controlling digestion and assimilation of nutrients. Another important indication of *chōng mài* is that it is the “rebellious or upward *qì*” and implies the perturbation or inversion of some physiological functions (nausea, vomiting, cough, palpitation, etc.).

Acupuncture Points

CV-1 *huì yīn*, ST-30 *qì chōng*, KI-11 *héng gǔ*, KI-12 *dà hè*, KI-13 *qì xué*, KI-14 *sì mǎn*, KI-15 *zhōng zhù*, KI-16 *huāng shū*, KI-17 *shāng qū*, KI-18 *shí guān*, KI-19 *yīn dū*, KI-20 *tōng gǔ (fù)*, KI-21 *yōu mén*.

Confluent Point

SP-4 *gōng sūn*.

Clinical Indications

Soma: thoracic and inguinal pain, paralysis and weakness of the upper limb.

Viscera: irregular menstruation, amenorrhea, metrorrhagia, spotting, infertility, leucorrhoea, insufficient lactation. Nausea, vomiting, belching, gastric pain, lack of appetite, abdominal distension, flatulence. Oppression and fullness of the chest, arrhythmia, palpitations.

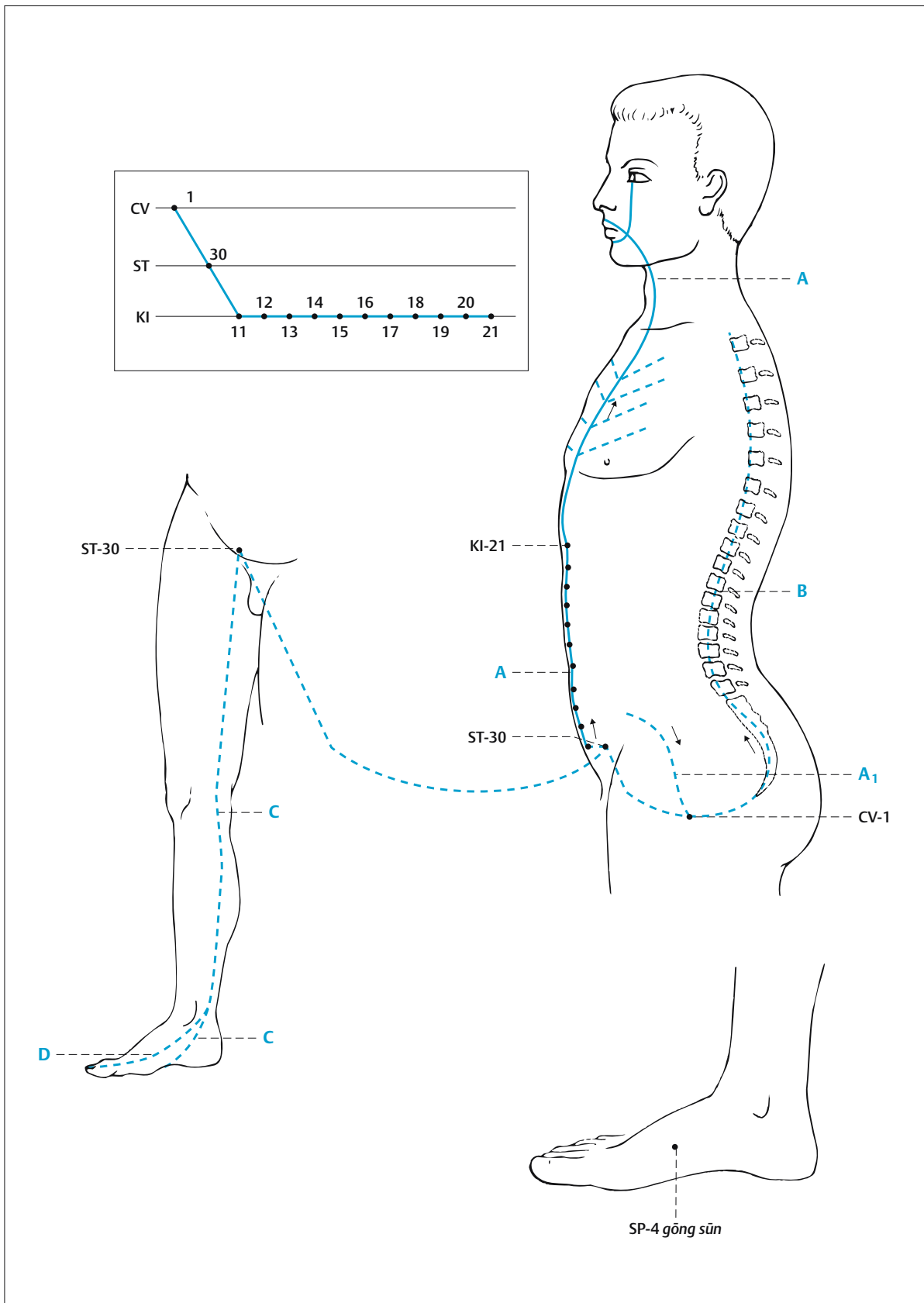


Fig. 4.3 The *chōng mài* extra channel.

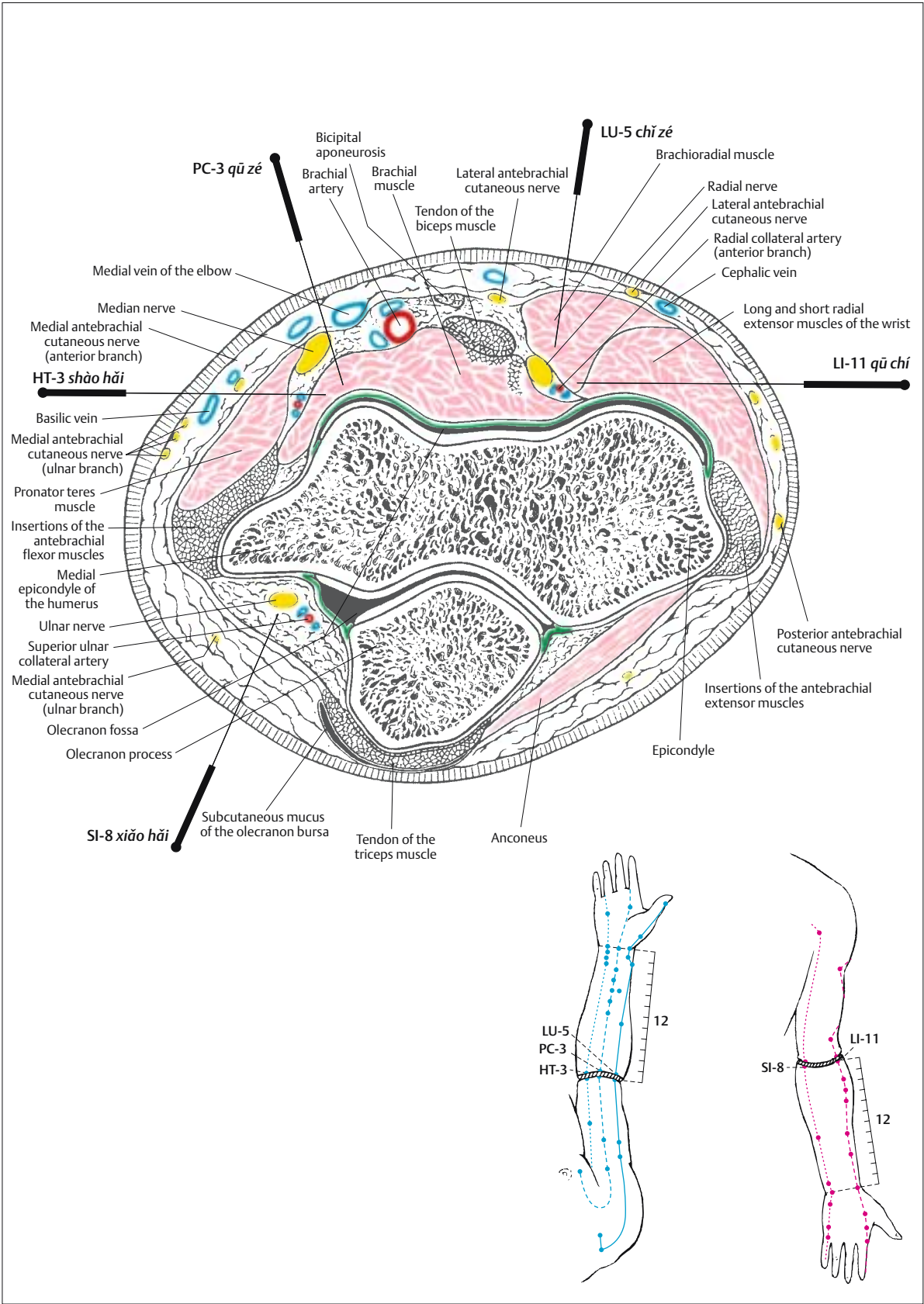


Fig. 8.34⁵ Cross-sectional study of points: LU-5 *chǐ zé*, LI-11 *qū chí*, HT-3 *shào hǎi*, SI-8 *xiǎo hǎi*, and PC-3 *qū zé*.

Point	Location	Method
ST-1 chéng qì Tear Container Fig. 6.1/6, 6.10/11 ⁵	Under the pupil, at the lower edge of the orbit, looking straight ahead. Posture: seated or supine, eyes closed. The eyeball is pushed and fixed upward. ¹	Needling method: perpendicular, along the lower wall of the orbit. Depth: 0.5–1 cun. The needle is inserted very slowly. No manipulation is required. De qi: local distension and soreness or radiating toward the eye. Moxa: no moxibustion. Remarks: avoid damaging the eye and relevant vessels and nerves. ¹
ST-2 sì bái Four Whites Fig. 6.1/6	1 cun below the pupil, looking straight ahead. At the infraorbital foramen and half way between the external canthus and the tip of the nose. Posture: seated or supine.	Needling method: perpendicular. Depth: 0.3–0.5 cun. De qi: numbness and a light electric sensation, sometimes radiating to the upper lip. Moxa: not recommended. Remarks: avoid deep needling, in order not to reach the vessels and nerves of the infraorbital foramen.
ST-3 jù liáo Greater Bone-Hole Fig. 6.1/6	Along the vertical line of the pupil, looking straight ahead. At the lower border of the nasal wings. Posture: seated or supine.	Needling method: perpendicular. Depth: 0.3–0.5 cun. De qi: local distension and soreness. Moxa: 3–5 cones; moxa rolls 15 minutes. Remarks: avoid the facial vessels during deep insertion.
ST-4 dì cāng Earth Granary Fig. 6.1/6	Along the vertical line of the pupil, looking straight ahead, 0.4 cun lateral to the junction of the lips. Posture: seated or supine.	Needling method: transverse, in the direction of the corner of the mandible. Length: 1–2 cun. De qi: local distension and soreness, sometimes radiating toward that side of the face. Moxa: 3–5 cones; moxa rolls 10 minutes.
ST-5 dà yíng Great Reception Fig. 6.3/6	Anterior to the angle of the mandible, along the frontal edge of the masseter muscle, in the depression formed when plumping out the cheeks. Posture: seated or supine.	Needling method: oblique. Depth: 0.3–0.5 cun. Needling method: perpendicular. Depth: 0.3 cun. De qi: local distension and numbness of the hemiface. Moxa: 3–5 cones; moxa rolls 15 minutes. Remarks: avoid the facial vessels below the point.
ST-6 jiá chē Cheek Carriage Fig. 6.3/6	One transverse finger's breadth in front of and above the corner of the mandible, on the prominence that becomes visible on the masseter muscle when clenching the teeth. Posture: seated or supine.	Needling method: perpendicular Depth: 0.3–0.5 cun. De qi: local distension and soreness. Needling method: oblique. ² Moxa: 3 cones; moxa rolls 5–10 minutes.
ST-7 xià guān Below the Joint Fig. 6.3/6	Below the lower edge of the zygomatic bone, in the depression that can be felt in front of the condyle of the mandible when the mouth is closed. Posture: seated or lying down on one side.	Needling method: perpendicular. Depth: 0.5–1 cun. De qi: local distension and soreness, sometimes radiating to the surrounding area and to the upper dental arch. Puncture: transverse and oblique puncture. ³ Moxa: 3 cones; moxa rolls 5–10 minutes. Remarks: avoid the maxillary vessels during deep insertion.
ST-8 tóu wéi Head Corner Fig. 6.1/6	0.5 cun within the hairline, at the upper-outer corner of the forehead, at 4.5 cun from <i>dū mài</i> . Posture: seated or supine.	Needling method: transverse, subcutaneous, toward the rear. Length: 0.5–1 cun. De qi: local distension and soreness or radiating to the surrounding area. Moxa: no moxibustion.

Anatomy

The needle crosses the skin, the subcutaneous tissue, the orbicular muscle of the eye, and the orbicular fatty tissue; if the point is directed upward it can reach the inferior oblique and rectus muscles.

In the superficial layer lie the infraorbital vessels and nerves (lower palpebral branch, V2) and the zygomatic branches of the facial nerve (VII).

In the deeper layer lie the muscular branch of the oculomotor nerve, the ophthalmic vessels, and the ophthalmic nerve.

The needle crosses the skin and subcutaneous tissue and, crossing between the levator muscle of the upper lip and orbicular muscle of the eye, reaches the infraorbital foramen.

In the superficial layer lie the cutaneous branches of the infraorbital nerve (V2) and, internally and below these, the facial artery and veins.

In the deeper layer lie the infraorbital vessels and nerves as they emerge from the infraorbital foramen.

The needle crosses the skin and subcutaneous tissue and, crossing between the levator muscle of the upper lip, may reach the levator muscle of the angle of the mouth.

In the superficial layer lie the cutaneous branches of the infraorbital nerve (V2) and of the infraorbital and facial vessels.

In the deeper layer lie the branches of the infraorbital nerve, the buccal branch of the facial nerve, and the facial artery and veins.

The needle crosses the skin, the subcutaneous tissue, and the orbicular muscle of the mouth and can reach the buccinator muscle of the mouth.

In the superficial layer lie the cutaneous branches of the infraorbital nerve (V2), of the buccal nerve (V3), and of the infraorbital and facial vessels.

In the deeper layer lie the branches of the infraorbital nerve, of the buccal branch of the facial nerve, and, posteriorly, of the facial artery and veins.

The needle crosses the skin and subcutaneous tissue and reaches the anterior edge of the masseter muscle.

In the superficial layer lie the cutaneous branches of the buccal nerve (V3), the marginal mandibular branch of the facial nerve (VII), and the facial vessels and their cutaneous branches.

In the deeper layer lie the vascular and nervous branches supplying the masseter muscle.

The needle crosses the skin and subcutaneous tissue and reaches the masseter muscle.

In the superficial layer lie the cutaneous branches of the great auricular nerve (C1–C3), the marginal mandibular branch of the facial nerve (VII), and the facial vessels and their cutaneous branches.

In the deeper layer lie the vascular and nervous branches supplying the masseter muscle.

The needle crosses the skin and subcutaneous tissue, passes anterior to the parotid and posterior to the masseter muscle, and can reach the lateral pterygoid muscle.

In the superficial layer lie the cutaneous branches of the auriculotemporal nerve (V3), the zygomatic branches of the facial nerve (VII), and the facial vessels.

In the deeper layer lie the lateral branches of the mandibular nerve (V3) the maxillary vessels, the masseter vessels and nerves, and the pterygoid plexus.

The needle crosses the skin, the subcutaneous tissue, and the epicranial aponeurosis and reaches the subaponeurotic loose connective tissue.

In this region lie branches of the zygomatic temporal nerve (V2), the auriculotemporal nerve (V3), and the superficial temporal vessels.

Clinical Indications

Eyesight disorders and eye diseases, redness, swelling, and pain of the eye, night blindness, photophobia, myopia, cataract, glaucoma, optic neuritis, strabismus.

Allergic oculorhinitis, sinusitis.
Facial palsy.

Eyesight disorders and eye diseases.
Allergic oculorhinitis, sinusitis.
Headache, trigeminal neuralgia, nervous tics, twitching of the eyelid.
Analgesia for eye surgery.

Eyesight disorders and eye diseases.
Allergic oculorhinitis, sinusitis.
Headache, trigeminal neuralgia, nervous tics, twitching of the eyelid.
Facial paralysis.
Toothache, swelling and inflammation of the face and cheek.

Facial paralysis, trigeminal neuralgia, twitching of the eyelid, facial tics.
Pain and contractures of the muscles of the cheeks, toothache.
Salivary incontinence.

Facial paralysis, lockjaw, toothache, parotitis.

Mandibular joint pain and ankylosis, neck pain and stiffness, toothache.
Facial paralysis, lockjaw, trigeminal neuralgia.
Parotitis.

Mandibular joint pain and ankylosis, neck pain and stiffness, toothache.
Facial paralysis, lockjaw, trigeminal neuralgia.
Ear pain, otitis, loss of hearing, deafness, tinnitus.

Headache, dizziness, facial paralysis.
Redness, swelling and pain of the eye, twitching of eyelid, allergic oculorhinitis.
Manic depressive psychosis.

Read instantly in your browser. Teaching Atlas of Acupuncture: Volume 1: Channels and Points (v. 1) 1st Edition. by Piero Ettore Quirico (Author), Tiziana Pedrali (Author). Be the first to review this item.Â This lavishly illustrated anatomic atlas of 414 pages by the Italian doctors Quirico and Pedrali provides the reader with concrete answers and reassurance on a wide range of questions pertaining to anatomy in acupuncture practice. The first section offers a concise review of all major acupuncture points, presenting their clinical applications in table format. This is followed by a second section of more than 200 full-color illustrations. Cross-sections depict concrete anatomic structures in the vicinity of each acupuncture point, illustrating skin, muscles, nerves, blood vessels, and bones.